



## Case Report

# Objective Improvements in Peripheral Arterial Disease from Dorsal Root Ganglion Stimulation: A Case Series

Kenneth B. Chapman,<sup>1,2,3</sup> Jaap Kloosterman,<sup>4</sup> Jonathan A. Schor,<sup>5</sup> George E. Girardi,<sup>6</sup> Noud van Helmond,<sup>1,7</sup> and Tariq A. Yousef<sup>†</sup>

**Background:** The sympathetic nervous system (SNS) is important in the regulation of perfusion. Dorsal root ganglion stimulation (DRG-S) modulates sympathetic tone and is approved to treat complex regional pain syndrome, a disorder related to SNS dysfunction. We herein present 3 cases of DRG-S therapy to improve blood flow and symptoms of ischemia in peripheral arterial disease (PAD).

**Methods:** Patient 1 is a 44-year-old female with dry gangrene of the third and fourth digits of her right hand due to Raynaud's syndrome who was scheduled for amputation of the affected digits. DRG-S leads were placed at the right C6, 7, and 8 DRG. Pulse volume recordings (PVR) were measured at baseline and after DRG-S. Patient 2 is a 55-year-old female with a non-healing ulcer of her left foot secondary to PAD scheduled for a below the knee amputation who underwent a DRG-S trial with leads placed at the left L4 and L5 DRG followed by a spinal cord stimulation trial with leads placed at the T9–T10 spinal levels for comparison. Transcutaneous oximetry (TcPO<sub>2</sub>) was measured at baseline and after 3 days of each therapy. Patient 3 is a 69-year-old female with persistent left foot pain at rest secondary to PAD with DRG-S leads placed at the left L4 and S1 levels.

**Results:** All 3 patients experienced a significant reduction in pain with DRG-S, along with improvements in blood flow of the involved extremities, avoiding or limiting amputation. PVR improved dramatically with DRG-S in patient 1. A greater improvement in TcPO<sub>2</sub> was seen with the DRG-S trial compared to spinal cord stimulation trial in patient 2. Patient 3 experienced an increase in walking distance and demonstrated long term efficacy and limb salvage at 32 months postimplantation.

**Conclusions:** Modulation of SNS output from DRG-S through orthodromic and antidromic autonomic pathways is likely responsible for improving blood flow. DRG-S may be a treatment option for PAD.

*Funding Information:* This project received no specific funding.

*Disclosures:* The authors have nothing to disclose.

<sup>1</sup>Spine & Pain Institute of New York, New York City, NY

<sup>2</sup>Department of Anesthesiology, New York University Langone Medical Center, New York City, NY

<sup>3</sup>Zucker School of Medicine at Hofstra/Northwell, New York City, NY

<sup>4</sup>College of Medicine, Radboud University, Nijmegen, The Netherlands

<sup>5</sup>Department of Surgery, Division of Vascular Surgery, Staten Island University Hospital, New York, NY

<sup>6</sup>Front Range Pain Medicine, Fort Collins, CO

<sup>7</sup>Department of Anesthesiology, Cooper Medical School of Rowan University, Cooper University Hospital, Camden, NJ

Correspondence to: Kenneth B. Chapman, 1360 Hylan Boulevard, Staten Island, NY 10305, USA; E-mail: [chapmanken@spinepainny.com](mailto:chapmanken@spinepainny.com)

Ann Vasc Surg 2021; 000: 1.e1–1.e10

<https://doi.org/10.1016/j.avsg.2021.01.069>

© 2021 Elsevier Inc. All rights reserved.

Manuscript received: November 25, 2020; manuscript revised: January 2, 2021; manuscript accepted: January 5, 2021; published online: xxx

## INTRODUCTION

Peripheral arterial disease (PAD) is a major cause of morbidity and mortality globally, with significant financial burden on healthcare resources.<sup>1</sup> PAD affects 10–15% of the US population and ~20% of people >60 years old, with well over 200 million affected globally according to a 2010 estimate.<sup>2</sup> Traditional spinal cord stimulation (SCS) is efficacious in the treatment of PAD<sup>3–6</sup> with improvements in pain, exercise tolerance, and limb salvage in patients with critical limb ischemia.<sup>4,7</sup> SCS improves cutaneous and muscle blood flow, likely through antidromic stimulation from the dorsal columns to the dorsal horn.<sup>8–13</sup> This is in contrast to surgical sympathectomy, which improves peripheral microvascular flow but not blood flow to musculature.<sup>14</sup> Neuromodulation has also been used in non-atherosclerotic peripheral vascular diseases, such as Raynaud's syndrome.<sup>15–19</sup>

Dorsal root ganglion stimulation (DRG-S) is a newer mode of neuromodulation indicated for the treatment of complex regional pain syndrome (CRPS), a chronic neuropathic pain disorder marked by sympathetic nervous system (SNS) dysfunction. The DRG houses the cell bodies of primary afferent neurons, making the DRG an optimal location to modulate all afferent nerve fiber types, including sympathetic fibers. Furthermore, DRG-S uses low-frequency, subthreshold stimulation that offers better dermatomal coverage of the distal extremities compared to SCS.<sup>20,21</sup>

Neural regulation of vascular tone is predicated on the frequency of action potential firing, as high frequency firing induces vasoconstriction, while low frequency firing induces vasodilation.<sup>22</sup> Vasoconstriction is a mechanism to regulate mean arterial pressure as well as local perfusion and can be influenced by endogenous and exogenous factors.<sup>23</sup> Thermoreceptors and nociceptors in the skin relay information regarding skin temperature to the spinal cord through somatic afferent C- and A- $\delta$  fibers, which pass through the DRG to the dorsal horn. Afferent signals are relayed to the hypothalamus, which controls the autonomic response. Efferent signals travel down the dorsal longitudinal fasciculus to reach sympathetic preganglionic neurons in the intermediolateral nucleus of the spinal cord. Preganglionic fibers exit through the ventral root and enter the sympathetic chain through the white ramus communicans to synapse onto sympathetic postganglionic neurons located in the paravertebral sympathetic ganglia. The postganglionic fibers, which are unmyelinated

C-fibers, exit the sympathetic chain through the grey ramus communicans to join the mixed spinal nerve at that level, and go on to innervate cutaneous blood vessels, signaling the release of norepinephrine and vasoconstricting neuropeptide in endothelial cells (Fig. 1A).<sup>24</sup>

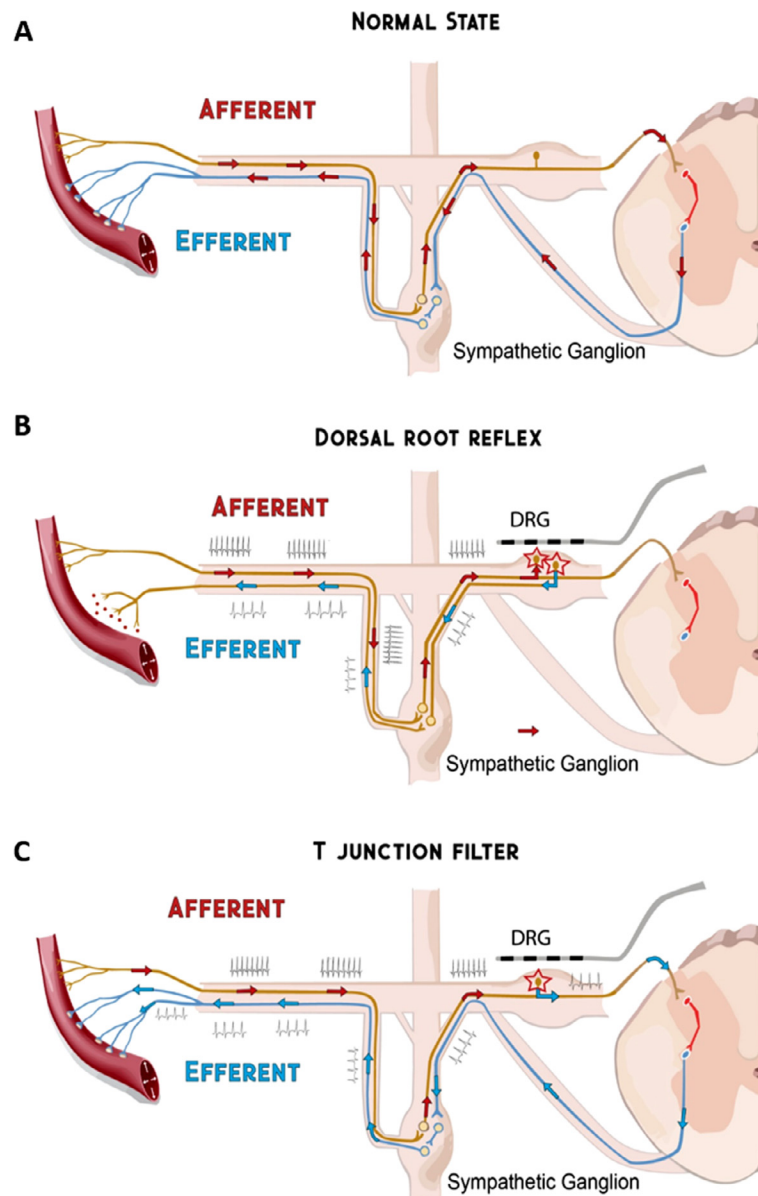
Primary sympathetic afferent fibers that innervate peripheral blood vessels have unique properties, including simultaneously acting as efferent fibers through dorsal root and axon reflexes. Upon activation, dorsal horn interneurons can reciprocally activate excitatory receptors on central terminals of the same afferent fibers to depolarize them such that a dorsal root reflex occurs. When this happens, antidromic action potentials travel to the peripheral terminals to cause release of peptides such as substance P to facilitate vasodilation - see Fig. 1B. A similar phenomenon known as an axon reflex occurs when action potentials generated at the sensory receptor endings of one branch reach an intersecting point with other branches on the axon and travel antidromically towards the peripheral terminal of another branch to induce the release of vasodilator substances—see Fig. 1B.<sup>24–28</sup>

There are several objective measures to determine blood flow to the distal extremities, including the ankle brachial index, pulse volume recording (PVR), and transcutaneous oximetry (TcPO<sub>2</sub>).<sup>29</sup> PVR is used to determine whether vascular disease has produced alterations to segmental arterial flow patterns. PVR is also used to differentiate between vasospastic and vaso-occlusive disease, in evaluating cold sensitivity, and monitoring response to medical and surgical treatments.<sup>30</sup> TcPO<sub>2</sub> is a non-invasive measure of oxygen levels below the skin and can be used as an indirect measure of blood flow.<sup>31,32</sup> TcPO<sub>2</sub> data can be used to evaluate the severity of tissue hypoxia from arterial insufficiency, as well as to predict the progression of PAD or the response to therapy.<sup>33</sup> A TcPO<sub>2</sub> <10 mm Hg is associated with a high rate of amputation<sup>34</sup>, and an increase in TcPO<sub>2</sub> following treatment often predicts limb salvage.<sup>5,35</sup>

The aim of this report is to describe 3 cases of peripheral vascular disease in which DRG-S was used to improve peripheral perfusion. All patients provided written informed consent for the publication of this report.

## CASE #1

A 44-year-old female with a history of severe Raynaud's syndrome, diabetes mellitus type 2, and

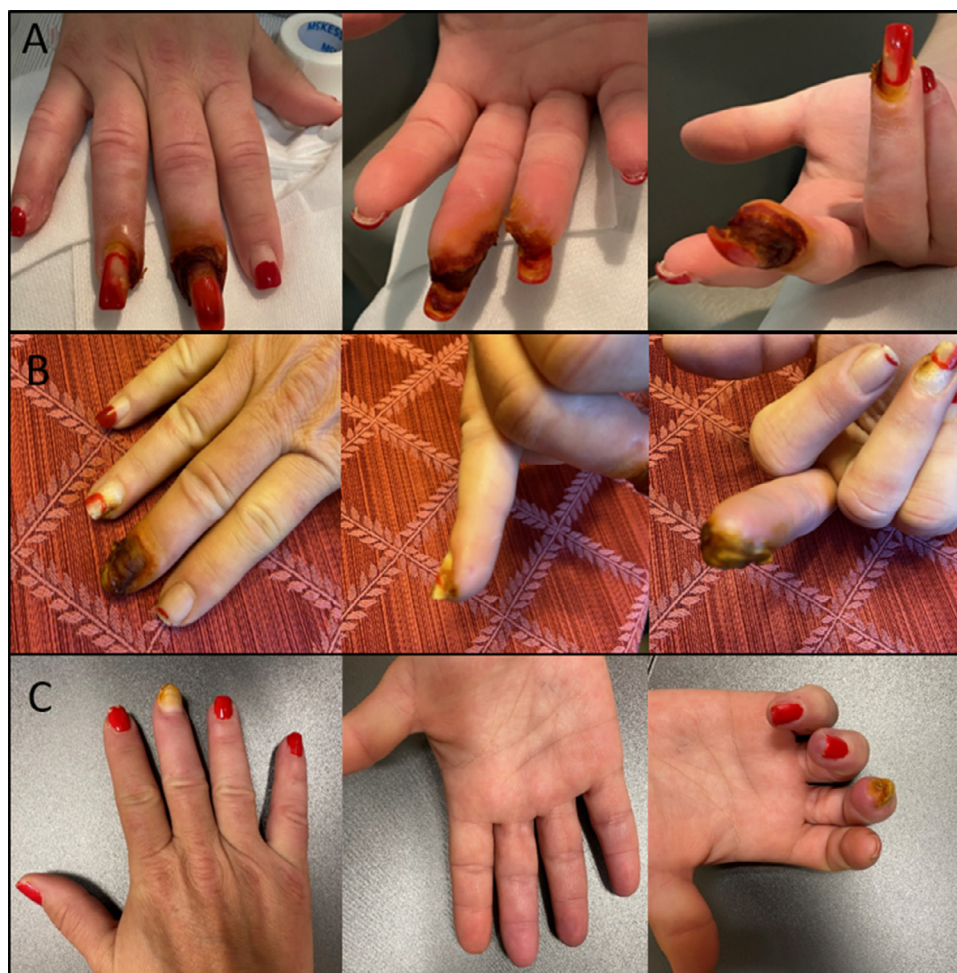

**Fig. 1.** Afferent and efferent components of sympathetic neural vasoconstriction. Red arrows represent normal signaling. Blue arrows represent DRG-S modulated signaling. Panel A: Afferent and efferent input involved in vasoconstriction. Panel B: Dorsal root reflex: The spinal cord can send signals antidromically down afferent fibers to the peripheral nerve endings to cause release of transmitters. DRG-S accentuates the effects. Panel C: T-junction filtering of high frequency action potentials at the DRG is enhanced by DRG-S.

a 15 pack-year history of smoking was referred to our institution by her vascular surgeon for stellate ganglion blocks. Four months prior to presentation she sustained minor paper cuts to the third and fourth digits of her right hand which progressed to ulcerations and eventually dry gangrene of the third and fourth fingertips—see Fig. 2. Prior treatment with sildenafil, nifedipine, gabapentin, botox injections, and 45 sessions of

hyperbaric oxygen treatment did not improve her symptoms. She was not deemed a candidate for revascularization by her vascular surgeon because a CT angiogram and selective angiography showed adequate blood flow across the palmar arch. When she presented at our institute, she rated the pain in her right hand a 10/10 on the numeric rating scale (NRS) and described it as constant and unremitting and associated with coldness of the fingertips. The



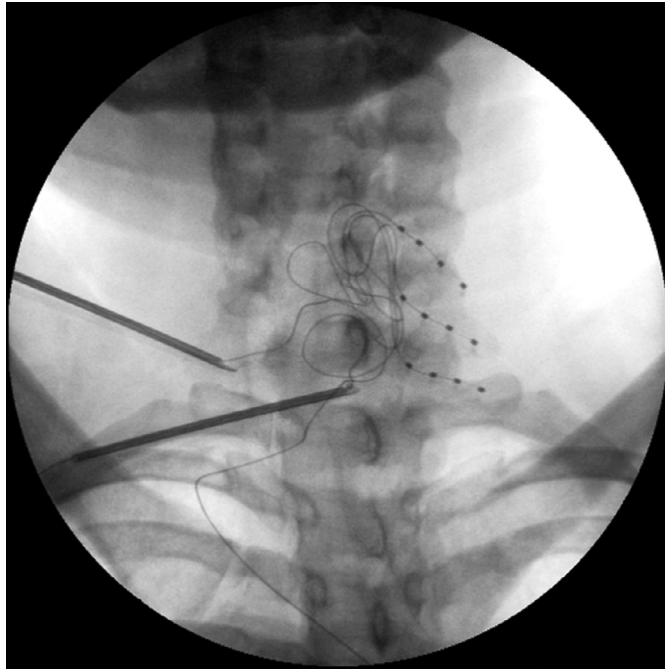


**Fig. 2.** Images of the right hand of 44-year old female with Raynaud's syndrome. Images at baseline (A), after 1 month of dorsal root ganglion stimulation (DRG-S), and after 6 months of DRG-S. DRG-S placed on the right C6, 7, and 8 DRGs resulted in digit salvage and a return to her normal functional status.

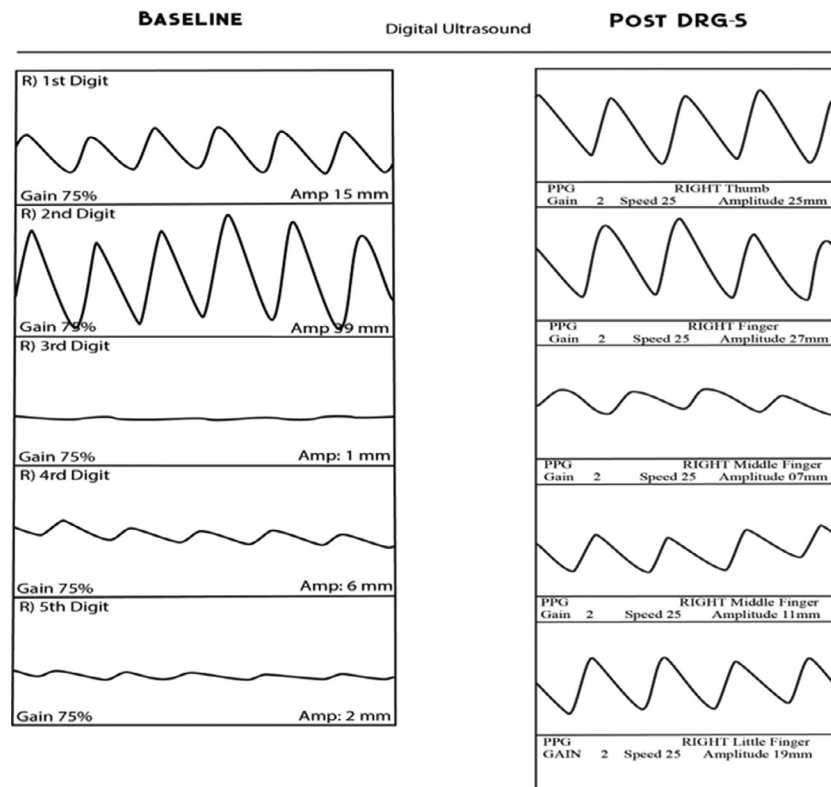
pain restricted her from being able to use her right hand to perform chores, frequently interrupted her sleep, and led her to take an extended leave of absence from work as an attorney. PVR of the right hand showed greatly reduced blood flow to the third, fourth, and fifth digits. She was prescribed acetaminophen/oxycodone 325/10 mg 4 times per day which gave her minimal pain relief and underwent 3 stellate ganglion blocks at our institute over the course of 3 weeks, with each block providing her temporary pain relief for 4–6 hours. Four weeks later, we proceeded with a tunneled 1-week DRG-S trial on the right side with leads at the C6, C7, and C8 DRGs to reduce pain and increase blood flow to the fingers in order to salvage the digits from amputation or at the very least limit the ulceration and gangrene in her fingertips if she required surgical debridement or amputation (Fig. 3). As per standard

practice, temporary leads were placed during the 1-week trial and connected to an externalized generator to evaluate therapy response, with success defined as >50% relief of pain and symptoms, prior to permanent implantation.

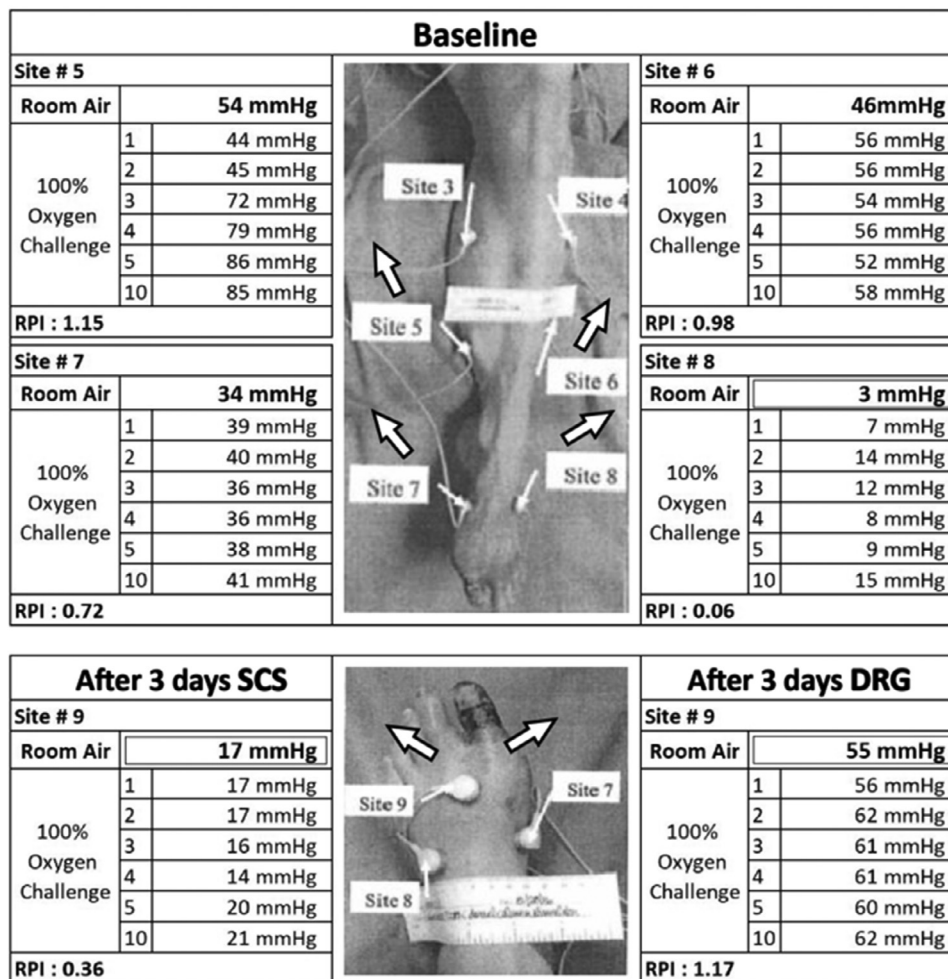Paresthesia-based programming was used to confirm proper lead placement after which the amplitude was lowered 0.025 mA below the paresthesia threshold to achieve subthreshold, paresthesia-free stimulation (frequency: 12 Hz, pulse width: 240 us, amplitude: 0.125–0.300 mA). PVR was repeated on day 4 of the DRG-S trial, demonstrating marked amplitude improvements of 83–850% in blood flow in the affected digits compared to 3 weeks prior to the trial (Fig. 4). Her NRS pain score decreased from a 10/10 to a 3/10 during the trial. She reduced her daily dose of opioid pain medication by 75%. Her sleep increased from 60–90 minutes per day to 4–5



**Fig. 3.** Fluoroscopic images of C6, 7, and 8 dorsal root ganglion stimulation (DRG-S) lead placements in a patient with Raynaud's syndrome.



**Fig. 4.** PVR before and after 4 days of DRG-S in a patient with Raynaud's syndrome. At baseline, PVR of the digits of the right hand showed greatly reduced blood flow to the third, fourth, and fifth digits. On day 4 of the DRG-S trial, marked amplitude improvements of 83–850% in blood flow were seen in the affected digits.



**Fig. 5.** TcPO<sub>2</sub> measurements in patient with PAD and ulceration of the left foot. Baseline TcPO<sub>2</sub> at the closest site to ulceration was 3 mm Hg on room air and improved to 15 mm Hg after 10 minutes of 100% oxygen challenge. After 3 days of SCS, the closest site to ulceration had a TcPO<sub>2</sub> of 17 mm Hg on room air and improved to 21 mm Hg after 10 minutes of 100% oxygen challenge. In comparison, after 3 days of DRG-S, the closest site to ulceration had a TcPO<sub>2</sub> of 55 mm Hg on room air and improved to 62 mm Hg after 10 minutes of 100% oxygen challenge.

hours of continuous uninterrupted sleep. Given her improvements, a permanent device was implanted 15 days after the trial. Six months after permanent implantation, her gangrenous fingertip completely healed (Fig. 2), and she was pain free and no longer required opioid analgesics. She experienced no further episodes of Raynaud's phenomenon in the digits of her right-hand.

## CASE #2

A 55-year-old female presented with type 2 diabetes and PAD with ulceration of the first digit of the left foot. She failed multiple conservative treatments including anticoagulants, opioids, gabapentin, amlodipine, and nitroglycerine. Additionally, she underwent a lumbar sympathetic block with 2

weeks of pain improvement. She was not deemed a candidate for a revascularization procedure by her vascular surgeon and was referred for consideration of neuromodulation therapy 2 months after the block. While SCS is an approved indication for PAD, we felt DRG-S might provide better distal extremity coverage than SCS, and the decision was made to trial both modes of neuromodulation. She experienced 9/10 NRS pain in her foot at baseline. TcPO<sub>2</sub> at the closest point to the ulceration was 3 mm Hg on room air, which improved to 15 mm Hg after ten minutes of 100% oxygen (Fig. 5). For the trial period, left L4 and L5 DRG-S leads were placed in addition to 2 SCS leads that were placed at the T9–10 junction of the dorsal columns.<sup>3</sup> The DRG-S leads were activated for the first 3 days



of the trial period, followed by a 3-day washout with no stimulation after which the SCS leads were turned on for 3 days.

On day 3 of the DRG-S trial, the TcPO<sub>2</sub> at the closest point to ulceration had increased to 55 mm Hg on room air and improved to 62 mm Hg after 10 minutes of 100% oxygen (Fig. 5). Pain improved to 1/10 on NRS with DRG-S. In comparison, after 3 days of SCS, the TcPO<sub>2</sub> score closest to the ulceration was 17 mm Hg on room air and improved to 21 mm Hg after 10 minutes of 100% oxygen (Fig. 5). Pain was 3/10 on NRS with SCS.

Despite the robust improvements with the DRG-S trial, the patient was implanted with an SCS system due to health insurance policy coverage restrictions. Three years after SCS system implantation, she maintained significant improvement of her symptoms, allowing her surgeon to salvage her leg and convert a planned below the knee leg amputation to a smaller transtatarsal amputation of the foot.

### CASE #3

A 69-year-old woman with severe left foot pain at rest secondary to PAD (Rutherford stage 4) was referred to our office by her vascular surgeon for consideration of a SCS trial. She had a history of atrial fibrillation, coronary artery disease, an implanted cardioverter defibrillator for arrhythmia, and low back pain secondary to facet arthrosis and spinal stenosis. She had a left femoral arterial occlusion which failed 2 prior femoral artery revascularization procedures. The next step under consideration for her treatment was limb amputation. She had constant pain in the left foot and lower leg rated 9/10 on NRS that she characterized as burning, sharp, and stabbing. She was taking 100 mg tramadol twice daily and 600 mg gabapentin 3 times a day with inadequate pain relief. On physical exam, her left foot was cold to touch and glossy in appearance with dusky colored skin. Allodynia and hyperesthesia were present throughout the entire foot. Her ankle brachial index was <0.5 on the left, consistent with critical ischemia of the lower limb.

To try to salvage the limb from amputation and improve pain symptoms, we proceeded with a DRG-S trial at the left T12, L4, and S1 DRGs to cover both her foot, leg, and low back pain. Given the severe localized pain in the distal lower limb, we chose DRG-S over SCS for better distal extremity coverage. Her pain score decreased from a 9/10 to a 2/10 on NRS at the end of the 7-day trial, and she

was implanted with a permanent device 2 weeks later. At 32 months postimplantation, she had no pain at rest (0/10 NRS) or during ambulation in the foot or leg, although her walking distance was limited by her spinal stenosis to 1 city block. She was able to avoid amputation and has required no further vascular intervention since implantation.

### DISCUSSION

After exhausting extensive conservative and interventional vascular treatments, DRG-S therapy was successfully utilized as a last resort for limb salvage in 2 of the 3 patients described in this report, and provided superior results to SCS therapy in the other patient. DRG-S resulted in marked improvements in both macrovascular and microvascular blood flow as evidenced by changes in PVR and TcPO<sub>2</sub>. These measurements were accompanied by visually evident tissue recovery, improvements in function and activity, and marked reductions in pain.

SCS has previously been shown to be an effective treatment for peripheral vascular disease.<sup>10,12</sup> SCS selectively targets afferent A $\beta$  fibers in the dorsal columns,<sup>36</sup> leading to gating mechanisms of incoming pain signals into the spinal cord at the dorsal horn.<sup>37</sup> DRG-S is a newer mode of neuromodulation that allows for modulation of more afferent fiber types and better coverage of distal dermatomes. Both SCS and DRG-S implantation are relatively safe procedures, with the most commonly reported complications being lead fracture, lead migration, pain at the generator pocket site, and infection, with a total incidence rate of approximately 3%.<sup>38,39</sup>

### Prior Studies

While previous studies regarding SCS therapy for PAD have been published, we are unaware of any studies pertaining to DRG-S therapy for the treatment of PAD. Tissue hypoxia of the lower limb is defined as a TcPO<sub>2</sub> below 40 mm Hg,<sup>40</sup> and a review of 11 studies demonstrated that a TcPO<sub>2</sub> of 20 mm Hg is a strong indicator for the need of limb amputation. A TcPO<sub>2</sub> of >30 mm Hg is required for wound healing after amputation, while a normal TcPO<sub>2</sub> in the foot is >50 mm Hg.<sup>41,42</sup> In the patient presented in case #2, TcPO<sub>2</sub> changed from 3 to 17 mm Hg with SCS, which is consistent with published studies.<sup>4,35</sup> However, the TcPO<sub>2</sub> increased to 55 mm Hg in response to DRG-S in the same patient, which was 3 times greater than the response to SCS, and a return to normalized levels.

A surgical sympathectomy can improve peripheral cutaneous microcirculation but does not affect blood flow to the underlying musculature, whereas SCS improves both.<sup>13,14</sup> DRG-S also improves circulation to both areas and may reduce arterial blood pressure as well as muscle sympathetic nervous activity.<sup>43</sup> We hypothesize that given the complex, intertwined network of the SNS, a surgical sympathectomy is sufficient to denervate cutaneous microvasculature and sensation via the sympathetic chain, but may be incomplete in targeting muscular blood flow and sympathetic innervation.<sup>44,45</sup> Clinically, this is demonstrated by the modest temperature and blood flow increases seen with a lumbar sympathetic block, as compared to profound changes seen with sympathectomy produced by epidural or spinal anesthesia.

Several case reports have been published regarding SCS use in patients with Raynaud's syndrome with good results,<sup>17-19</sup> but a literature search found no publications pertaining to DRG-S as a treatment for Raynaud's. In the patient presented in case #1, pain decreased from an NRS of 10/10 to 4/10 with concomitant improvements in sleep, function, and decrease in opioid use with a cervical DRG-S trial. Robust improvements in blood flow were demonstrated ranging from 60% in the thumb to 850% in the fifth digit. Blood flow in the second digit decreased 31%, but remained in the normal range, which may represent re-distribution of collateral circulation to the perfused digits. Importantly, the second finger exhibited no signs of ischemia before or after DRG-S. Interestingly, the pain caused by the necrosis in her fingers would be characterized as acute to subacute nociceptive pain, which typically does not respond to SCS. The healing of the digits, combined with improvements in function, pain, and dramatic improvements in blood flow as measured by PVR support the efficacy of DRG-S in treating vasospastic disorders.

### Potential Physiological Underlying Mechanisms

DRG-S likely exerts its effects on vascular tone through multiple processes, including increased action potential filtering at the T-junction within the DRG, through potential antidromic mechanisms including dorsal root reflexes,<sup>20,46,47</sup> and orthodromic processes within the spinal cord. Additionally, the SNS has been described as an amplifier of neural transmission. The ratio of sympathetic preganglionic (white rami communicantes) neurons to postganglionic (grey rami communicantes) neurons is anywhere

from 1:4 to 1:32,<sup>48</sup> with 1 preganglionic neuron synapsing on postganglionic neurons at multiple levels, thus amplifying the signal being transmitted to multiple neural interfaces. Regarding the role of DRG-S interfacing with these systems the following possible mechanisms are postulated:

1. T-junction filtering: Enhanced filtering of high frequency firing of afferent fibers at the DRG in turn decreases sympathetic output, leading to reduced vasoconstriction and net vasodilation—see Figure 1c.
2. Dorsal root reflex: Electrical stimulation of the proximal spinal nerve at the DRG with DRG-S induces the dorsal root reflex to facilitate vasodilation through antidromic signalling<sup>26</sup>—Figure 1b.
3. Orthodromic propagation: Orthodromic propagation of low frequency action potentials along afferent sympathetic fibers that synapse and activate sympathetic preganglionic neurons in the spinal cord may have far-reaching effects beyond the DRG level being stimulated through the SNS signal amplification described above.

### Conclusion

DRG-S may be an effective treatment for atherosclerotic or vasospastic ischemia due to PAD or Raynaud's syndrome. Underlying mechanisms likely involve modulation of SNS activity through processes at the DRG, sympathetic chain, and the spinal cord. Larger prospective studies are needed to corroborate the effectiveness of DRG-S in peripheral vascular diseases.

### REFERENCES

1. Malone M, Lau NS, White J, et al. The effect of diabetes mellitus on costs and length of stay in patients with peripheral arterial disease undergoing vascular surgery. *Eur J Vasc Endovasc Surg* 2014;48:447–51.
2. Fowkes FGR, Rudan D, Rudan I, et al. Comparison of global estimates of prevalence and risk factors for peripheral artery disease in 2000 and 2010: a systematic review and analysis. *Lancet* 2013;382:1329–40.
3. Ubbink DT, Vermeulen H. Spinal cord stimulation for non-reconstructable chronic critical leg ischaemia. *Cochrane Database Syst Rev* 2013;3:CD004001.
4. Amann W, Berg P, Gersbach P, et al. Spinal cord stimulation in the treatment of non-reconstructable stable critical leg ischaemia: results of the European peripheral vascular disease outcome study (SCS-EPOS). *Eur J Vasc Endovasc Surg* 2003;26:280–6.
5. Petrakis IE, Sciacca V. Spinal cord stimulation in diabetic lower limb critical ischaemia: transcutaneous oxygen measurement as predictor for treatment success. *Eur J Vasc Endovasc Surg* 2000;19:587–92.



6. Kumar K, Toth C, Nath RK, et al. Improvement of limb circulation in peripheral vascular disease using epidural spinal cord stimulation: a prospective study. *J Neurosurg* 1997;86:662–9.
7. Huber SJ, Vaglienti RM, Huber JS. Spinal cord stimulation in severe, inoperable peripheral vascular disease. *Neuromodulation* 2000;3:131–43.
8. Deer TR. Spinal cord stimulation for the treatment of angina and peripheral vascular disease. *Curr Pain and Headache Rep* 2009;13:18–23.
9. Liu J, Su C, Chen S, et al. Spinal cord stimulation improves the microvascular perfusion insufficiency caused by critical limb ischemia. *Neuromodulation* 2018;21:489–94.
10. Klinkova A, Kamenskaya O, Ashurkov A, et al. The clinical outcomes in patients with critical limb ischemia one year after spinal cord stimulation. *Ann Vasc Surg* 2020;62:356–64.
11. Tallis RC, Illis LS, Sedgwick EM, et al. Spinal cord stimulation in peripheral vascular disease. *J Neurol Neurosurg Psychiatry* 1983;46:478–84.
12. Tiede JM, Huntoon MA. Review of spinal cord stimulation in peripheral arterial disease. *Neuromodulation* 2004;7:168–75.
13. Linderoth B, Gunasekera L, Meyerson BA. Effects of sympathectomy on skin and muscle microcirculation during dorsal column stimulation: animal studies. *Neurosurgery* 1991;29:874–9.
14. Masuoka S, Shimomura T. Lumbar sympathectomy and blood flow in the lower extremity. *Am J Surg* 1978;136:369–74.
15. Provenzano DA, Nicholson L, Jarzabek G, et al. Spinal cord stimulation utilization to treat the microcirculatory vascular insufficiency and ulcers associated with scleroderma: a case report and review of the literature. *Pain Med* 2011;12:1331–5.
16. Francaviglia N, Silvestro C, Maiello M, et al. Spinal cord stimulation for the treatment of progressive systemic sclerosis and Raynaud's syndrome. *Br J Neurosurg* 1994;8:567–71.
17. Ting JC, Fukshansky M, Burton AW. Treatment of refractory ischemic pain from chemotherapy-induced Raynaud's syndrome with spinal cord stimulation. *Pain Pract* 2007;7:143–6.
18. Benyamin R, Kramer J, Vallejo R. A case of spinal cord stimulation in Raynaud's phenomenon: can subthreshold sensory stimulation have an effect? *Pain Physician* 2007;10:473–8.
19. Wolter T, Kieselbach K. Spinal cord stimulation for Raynaud's syndrome: long-term alleviation of bilateral pain with a single cervical lead. *Neuromodulation* 2011;14:229–32.
20. Deer TR, Pope JE, Lamer TJ, et al. The neuromodulation appropriateness consensus committee on best practices for dorsal root ganglion stimulation. *Neuromodulation* 2019;22:1–35.
21. Chapman KB, Yousef TA, Vissers KC, et al. Very low frequencies maintain pain relief from dorsal root ganglion stimulation: an evaluation of dorsal root ganglion neurostimulation frequency tapering. *Neuromodulation* 2020 (epub before print ner.13322) E pub ahead of print.
22. Johnson JM, Yen TC, Zhao K, et al. Sympathetic, sensory, and nonneuronal contributions to the cutaneous vasoconstrictor response to local cooling. *Am J Physiol Heart Circ Physiol* 2005;288:57–4.
23. Fardoun MM, Nassif J, Issa K, et al. Raynaud's phenomenon: a brief review of the underlying mechanisms. *Front Pharmacol* 2016;7:438.
24. Glatte P, Buchmann SJ, Hijazi MM, et al. Architecture of the cutaneous autonomic nervous system. *Front Neurol* 2019;10:970.
25. Wang J, Ren Y, Zou X, et al. Sympathetic influence on capsaicin-evoked enhancement of dorsal root reflexes in rats. *J Neurophysiol* 2004;92:2017–26.
26. Lobanov OV, Peng YB. Differential contribution of electrically evoked dorsal root reflexes to peripheral vasodilatation and plasma extravasation. *J Neuroinflammation* 2011;8:20.
27. Sorkin LS, Eddinger KA, Woller SA, et al. Origins of antidromic activity in sensory afferent fibers and neurogenic inflammation. *Semin Immunopathol* 2018;40:237–47.
28. Musa R, Qurie A. Raynaud disease (Raynaud phenomenon, Raynaud syndrome). *StatPearls* 2020. StatPearls Publishing Available at: <http://www.ncbi.nlm.nih.gov/pubmed/29763008> Accessed February 28, 2020.
29. Kumar K, Toth C, Nath RK, et al. Epidural spinal cord stimulation for treatment of chronic pain—some predictors of success. A 15-year experience. *Surg Neurol* 1998;50:110–20.
30. Kleinert JM, Gupta A. Pulse volume recording. *Hand Clin* 1993;9:13–46.
31. Yamada T, Ohta T, Ishibashi H, et al. Clinical reliability and utility of skin perfusion pressure measurement in ischemic limbs—comparison with other noninvasive diagnostic methods. *J Vasc Surg* 2008;47:318–33.
32. Trinks TP, Blake DF, Young DA, et al. Transcutaneous oximetry measurements of the leg: comparing different measuring equipment and establishing values in healthy young adults. *Diving Hyperb Med* 2017;47:82–7.
33. Kmiec MM, Hou H, Lakshmi Kuppasamy M, et al. Transcutaneous oxygen measurement in humans using a paramagnetic skin adhesive film. *Magn Reson Med* 2019;81:781–94.
34. Ubbink DT, Spincemille GHJJ, Reneman RS, et al. Prediction of imminent amputation with non-reconstructible leg ischemia by means of microcirculatory investigations. *J Vasc Surg* 1999;30:114–21.
35. Gersbach P, Hasdemir MG, Stevens RD, et al. Discriminative microcirculatory screening of patients with refractory limb ischaemia for dorsal column stimulation. *Eur J Vasc Endovasc Surg* 1997;13:464–71.
36. Sdrulla A, Guan Y, Raja S. Spinal cord stimulation: clinical efficacy and potential mechanisms. *Pain Pract* 2019;18:1048–67.
37. Melzack R, Wall PD. Pain mechanisms: a new theory. *Science* 1965;150:971–8.
38. Huygen FJPM, Kallewaard JW, Nijhuis H, et al. Effectiveness and safety of dorsal root ganglion stimulation for the treatment of chronic pain: a pooled analysis. *Neuromodulation* 2020;23:213–21.
39. Deer T, Pope J, Hunter C, et al. Safety analysis of dorsal root ganglion stimulation in the treatment of chronic pain. *Neuromodulation* 2020;23:239–44.
40. Blake DF, Young DA, Brown LH. Transcutaneous oximetry: variability in normal values for the upper and lower limb. *Diving Hyperb Med* 2018;48:2–9.
41. Byrne P, Provan JL, Ameli FM, et al. The use of transcutaneous oxygen tension measurements in the diagnosis of peripheral vascular insufficiency. *Ann Surg* 1984;200:159–65.

42. Fife CE, Smart DE, Sheffield PJ, et al. Transcutaneous oximetry in clinical practice: consensus statements from an expert panel based on evidence. *Undersea Hyperb Med* 2009;36:43–53.
43. Sverrisdottir YB, Martin SC, Hadjipavlou G, et al. Human dorsal root ganglion stimulation reduces sympathetic outflow and long-term blood pressure. *JACC Basic to Transl Sci* 2020;5:973–85.
44. Webber RH. An analysis of the cross communications between the sympathetic trunks in the lumbar region in man. *Ann Surg* 1957;145:355–70.
45. Kleiman A. Causalgia; evidence of the existence of crossed sensory sympathetic fibers. *Am J Surg* 1954;87:839–41.
46. Chapman KB, Groenen PS, Vissers KC, et al. The pathways and processes underlying spinal transmission of low back pain: observations from dorsal root ganglion stimulation treatment. *Neuromodulation* 2020 (Epub ahead of print ner.13150) pub ahead of print.
47. Chapman KB, Yousef TA, Foster A, et al. Mechanisms for the clinical utility of low-frequency stimulation in neuromodulation of the dorsal root ganglion. *Neuromodulation* 2020 (Epub ahead of print ner.13323) pub ahead of print.
48. Wolf Jr GA. The ratio of preganglionic neurons to postganglionic neurons in the visceral nervous system. *J Comp Neurol* 1941;75:235–43.